



Clinical practice guidelines

**Physiotherapy and orthopaedic treatment  
for isolated congenital foot deformity  
during the first six months of life**

January 2004

These guidelines on rehabilitation for isolated congenital foot deformity during the first six months of life were produced at the request of the *Association nationale des kinésithérapeutes salariés*.

They were produced using the method described in the guide "Clinical Practice Guidelines – Methodology to be used in France – 1999", published by ANAES.

The following learned societies were consulted:

- *Association française pour la recherche et l'évaluation en kinésithérapie;*
- *Association nationale des kinésithérapeutes salariés;*
- *Association nationale des médecins spécialistes en rééducation;*
- *Association nationale des puéricultrices diplômées d'État;*
- *Association nationale pour la recherche et l'évaluation en podologie;*
- *Association des sages-femmes enseignantes françaises;*
- *Fédération nationale des pédiatres néonatalogistes;*
- *Groupe d'étude de l'appareil locomoteur pédiatrique;*
- *Groupe d'étude en orthopédie pédiatrique;*
- *Société française de chirurgie orthopédique et traumatologique;*
- *Société française de kinésithérapie;*
- *Société française de médecine physique et de réadaptation;*
- *Société française de pédiatrie.*

The work was coordinated by Joëlle André-Vert, project manager, under the supervision of Dr. Patrice Dosquet, head of the Guidelines Department.

Documentary research was carried out by Emmanuelle Blondet with the help of Laurence Frigère, under the supervision of Rabia Bazi, head of the ANAES Documentation Department and also by Odile Messmer, Fabienne Rosato and Marie Vallas of the Reedoc Documentation Department of the Institut Régional de Réadaptation de Nancy.

Secretarial services were provided by Isabelle Le Puil.

ANAES would like to thank members of the Steering Committee and Working Group, peer reviewers, and the members of the Scientific Council who took part in this project.

---

## STEERING COMMITTEE

---

Dr. Françoise Beltramo, specialist in physical and rehabilitation medicine, Vandœuvre-lès-Nancy

Dr. Patricia Blondel, specialist in physical and rehabilitation medicine, Paris

Jeanine Dorbes, child carer, Toulouse

Dr. Véronique Forin, specialist in physical and rehabilitation medicine, Paris

Dr. Christine Francoual, paediatrician, Paris

Jean-Pierre Godard, physiotherapist, Vitry-sur-Seine

Martine Hedreul-Vittet, physiotherapist, Paris

Brigitte Herissé-Aumont, podiatrist, Toulouse

Dr. Jean Langlais, paediatric orthopaedic surgeon, Paris

Rémi Rémondière, physiotherapist, Villejuif

Dr. Christine Thémar-Noël, specialist in physical and rehabilitation medicine, Paris

Nadine Vassort-Pezet, midwife, Échirolles

---

## WORKING GROUP

---

Professor Jean-Philippe Cahuzac, paediatric orthopaedic surgeon, Toulouse – Chairman

Claude Marchal, physiotherapist, Aubure – Report author

Joëlle André-Vert, ANAES, Saint-Denis - Project manager

Dr. Stéphanie Bollie, paediatrician, Bondy

Dr. Madeleine Chapuis, paediatric orthopaedic surgeon, Rennes

Bernard Chastan, physiotherapist, Boulogne

Denis Chatel, physiotherapist, Paris

Régine Chedeville, physiotherapist, Paris

Dr. Pierre Chrestian, paediatric orthopaedic surgeon, Marseille

Frédérique Diméglio, physiotherapist, Palavas-les-Flots

Lydie Ginard, child carer, Saint-Quentin

Laurence Heim, midwife, Gérardmer

Dr. Serge Piroux, general practitioner, Craponne-sur-Arzon

Marie-José Pittet-Villaba, physiotherapist, Lyon

Dr. Francine Rumeau, specialist in physical and rehabilitation medicine, Flavigny-sur-Moselle

Jean-Pierre Salasc, physiotherapist, Paris

Dr. Philippe Souchet, paediatric orthopaedic surgeon, Paris

---

## PEER REVIEWERS

---

Dr. Gérard Andréotti, general practitioner, La Crau

Antoine Baïada, physiotherapist, Marseille

Marie Barthélémy, podiatrist, Ammerschwihl

Dr. Françoise Beltramo, specialist in physical and rehabilitation medicine, Vandœuvre-lès-Nancy

Jacques Bernard, physiotherapist, Craponne-sur-Arzon

Dr. Patricia Blondel, specialist in physical and rehabilitation medicine, Paris

Dr. Jean-Marie Blouët, paediatric orthopaedic surgeon, Laval

Sylvie Boissou, physiotherapist, Limoges

Anne-Marie Briard, physiotherapist, Saint-Maurice

Jean-Claude Brien, physiotherapist, Viriat

Dr. Franck Chotel, paediatric orthopaedic surgeon, Lyon

Dr. Anne Cortey, paediatrician/neonatologist, Créteil

Christelle Cusant, physiotherapist, Saint-Romans

Jean-Pierre Delaby, physiotherapist, Paris

Françoise Devaud, physiotherapist, L'Isle-d'Espagnac

Yves Doinel, physiotherapist, Noisy-le-Roi

Jeanine Dorbes, child carer, Toulouse

Dr. Éric Drahi, general practitioner, Saint-Jean-de-Braye

Frédéric Dubois, physiotherapist, Amiens

Philippe Durafourg, physiotherapist, Courbevoie

Marc Flipo, physiotherapist, Arpajon-sur-Cère

Dr. Véronique Forin, specialist in physical and rehabilitation medicine, Paris

Dr. Christine Francoual, paediatrician, Paris

Jean-Pierre Godard, physiotherapist, Vitry-sur-Seine  
Sylvie Gorin-Tauchet, physiotherapist, Caluire  
Dr. Thierry Haumont, paediatric orthopaedic surgeon, Vandœuvre-lès-Nancy  
Martine Hédreul-Vittet, physiotherapist, Paris  
Brigitte Hérissé-Aumont, podiatrist, Toulouse  
Christine Houvenaghel, physiotherapist, Lille  
Dr. Claire Hubert, paediatrician, Nancy  
Dr. Claude Karger, paediatric orthopaedic surgeon, Strasbourg  
Dr. Jean Langlais, paediatric orthopaedic surgeon, Paris  
Jean-Paul Larribau, physiotherapist, Pau  
Professor Pierre Lascombes, paediatric orthopaedic surgeon, Vandœuvre-lès-Nancy  
Gérard Marion, physiotherapist, Montbeton  
Dr. Pierre Mary, paediatric orthopaedic surgeon, Paris  
Professor Philippe Merloz, orthopaedic surgeon, Grenoble  
Jacques Monet (member of ANAES Scientific Council) physiotherapist, Paris  
Jacques Mugnier, physiotherapist, Nancy  
Michel Paparemborde (member of ANAES Scientific Council) physiotherapist, Lille  
Dr. Henry Parent, orthopaedic surgeon, Trélazé

Dr. Karine Patte, specialist in physical and rehabilitation medicine, Palavas-les-Flots  
Yves Postil, physiotherapist, Chasseneuil  
Laurence Quenneville, midwife, Paris  
Dr. Paul Rebuffel, paediatrician, Aubagne  
Rémi Rémondière, physiotherapist, Villejuif  
Claude Richet, physiotherapist, Montreuil  
Martine Rigal, physiotherapist, Toulouse  
Éric Roussel, physiotherapist, Les Clayes-sous-Bois  
Olivier Roux, physiotherapist, Plaisir  
Marie-Claude Selosse, child carer, Créteil  
Bertrand Steimer, physiotherapist, Strasbourg  
Jean-Pierre Tétard, physiotherapist, Berck-sur-Mer  
Dr. Christine Thémar-Noël, specialist in physical and rehabilitation medicine, Paris  
Marc Thuilot, physiotherapist, Amiens  
Nadine Vassort-Pezet, midwife, Échirolles  
Véronique Vion, physiotherapist, Grenoble

---

## GUIDELINES

---

These guidelines concern rehabilitation of isolated congenital foot deformity during the first 6 months of life. They do not cover foot deformities with associated disease or malformation, isolated malpositioning of the toes or the rare instances of isolated congenital pes cavus. They are intended for all healthcare professionals involved in diagnosing, monitoring or treating isolated congenital foot deformity. The guidelines were the subject of agreement among professionals when no level of scientific evidence could be established from a critical review of the literature<sup>1</sup>.

### I. DEFINITIONS

These guidelines concern the following deformities:

- *talipes calcaneus*: the foot is in dorsiflexion with limitation of plantar flexion of the ankle; it may be combined with valgus of the calcaneopedal block (*talipes calcaneovalgus*);
- *talipes varus*: supination of the whole calcaneopedal block, with normal ankle joint motion in the sagittal plane;
- *metatarsus varus* (sometimes called *metatarsus adductus*): adduction of the forefoot; may be combined with a hindfoot deformity;
- *talipes equinovarus* (TEV) (also called clubfoot): a three-dimensional inverted deformity, combining equinus and varus of the hindfoot, and adduction of the subtalar and midtarsal joint;
- *vertical talus* (*convex pes valgus*): dorsal luxation of the midtarsal joint, notably the talonavicular joint, combined to some extent with equinus of the hindfoot.

Surgery is:

- never necessary in *talipes calcaneus* or *talipes varus*
- necessary in fewer than 5% of cases of *metatarsus varus*
- necessary in over 5% of cases of *talipes equinovarus* and *vertical talus*.

### II. DIAGNOSIS AND REFERRAL TO A SPECIALIST

#### II.1. Prenatal examination

When prenatal ultrasonography reveals a foot deformity, arrangements should be made for the family to see a paediatric specialist, preferably an orthopaedic surgeon or a specialist in physical and rehabilitation medicine, who will explain the disorder and facilitate arrangements for care when the child is born.

---

<sup>1</sup> Guidelines are graded as follows:

- A grade A guideline is based on scientific evidence established by trials of a high level of evidence, e.g. randomised controlled trials (RCTs) of high power and free of major bias, and/or meta-analyses of RCTs or decision analyses based on properly conducted studies;
- A grade B guideline is based on presumption of a scientific foundation derived from studies of an intermediate level of evidence, e.g. RCTs trials of low power, well-conducted non-randomised controlled trials or cohort studies;
- A grade C guideline is based on studies of a lower level of evidence, e.g. case-control studies or case series.

## **II.2. Postnatal examination**

### ***Initial medical examination: diagnosing an isolated foot disorder***

If a foot deformity is observed at birth, the child must undergo a full clinical examination by a paediatrician or the maternity unit doctor before leaving. The aim of this examination is to:

- confirm that the child has a foot disorder. In a neonate born at term, a normal foot has dorsal flexion  $> 50^\circ$ , ankle joint movement in the sagittal plane  $>70^\circ$ , a straight lateral border of the foot and no skin creases;
- verify that the foot disorder is an isolated abnormality, by looking for any concomitant - particularly orthopaedic or neurological - disorders or malformations;
- establish a differential diagnosis between the different types of isolated foot disorder.

### ***Clinical examination of the foot by a specialist to assess the severity of deformity***

In the event of a foot deformity, even a minor one, the working group recommended that a detailed clinical examination of the foot, including skin, joints and muscles, should be carried out before the child leaves the maternity unit to:

- assess the initial severity of the deformity;
- decide how to treat the child depending on the disorder and its initial severity.

This examination is carried out by a paediatrician, physiotherapist, specialist in rehabilitation medicine, or orthopaedic surgeon depending on the facilities available in the health care organisation.

The Bleck classification of metatarsus adductus (Annex I) and the Diméglio classification of clubfoot (Annex II) should be used.

## **III. THE OPTIONS: MONITORING OR TREATMENT**

Whether a deformity should be treated or not depends on the medical diagnosis, assessment of severity, and the natural history of the deformity. Specialist examination of the foot will identify the clinical factors on which the decision to monitor or treat the deformity is based. These criteria are summarised in Annex III and reflect a high level of agreement among professionals.

### **III.1. Monitoring of spontaneous resolution of deformities**

Simple monitoring of spontaneous resolution is recommended for the following minor deformities:

- ordinary talipes calcaneus or talipes calcaneovalgus, where the lateral border is straight and the movement of the ankle joint allows the foot to be approximated to a right angle with the lower tibia ;
- talipes varus;
- mild and flexible metatarsus adductus where the heel-bisector line at rest passes through the 3rd toe, and where passive reduction can bring the forefoot into the neutral position.

The child is monitored by his or her doctor and should be referred to a paediatric orthopaedic specialist if spontaneous correction does not result, within 2 months, in recovery of a full range of movement in the ankle, pronation and supination movements of the hindfoot and a straight lateral border of the foot.

### **III.2. Treatment of deformities**

All the following deformities should be treated from the first week of life:

- ordinary talipes calcaneus where the anterior tibial muscle is stiff, preventing passive manipulation of the foot into a right angle with the lower tibia; and talipes calcaneovalgus, where the lateral border of the foot is concave;
- rigid, moderate or severe metatarsus adductus, where the heel-bisector line at rest bisects the 3<sup>rd</sup> and 4<sup>th</sup> toes, or where passive reduction cannot bring the foot into a neutral forefoot position;
- metatarsus adductus combined with a hindfoot deformity;
- talipes equinovarus;
- vertical talus.

### ***Metatarsus adductus and talipes calcaneus***

When treatment of metatarsus adductus and talipes calcaneus is indicated at birth, the treatment of choice is a combination of continuous passive motion, active mobilisation and removable braces. Clinical progress should be monitored by the child's doctor and a physiotherapist. If the deformity is not sufficiently corrected after 2 months of properly conducted treatment, the child should undergo diagnostic assessment by a paediatric orthopaedic specialist.

### ***Talipes equinovarus (clubfoot)***

Treatment of clubfoot requires close cooperation between the family and the professionals involved, i.e. a paediatric orthopaedic surgeon, physiotherapist and specialist in rehabilitation medicine who have a special interest in this disorder and are trained to treat it.

There are 3 different approaches to treating clubfoot:

- (i) functional treatment by a combination of mobilisation and removable braces;
- (ii) mixed therapy combining plaster cast and mobilisation;
- (iii) serial casting followed by application of a brace.

These approaches have not been compared in prospective trials, so no one approach has been shown to be better than the others (grade B). All three give satisfactory functional results without systematically resorting to surgery (grade B).

In functional or mixed treatment, some teams use mobilisation by a continuous passive motion machine. This delays surgery and reduces the number of the most extensive procedures during the first year (grade C). However, there is no agreement among professionals on its use for rehabilitation for clubfoot.

For treatment by serial casting followed by application of a brace, a plaster cast made by the Ponseti technique, combined if necessary with Achilles tendon tenotomy, reduces the rate of surgical posteromedial soft-tissue release compared to the use of Kite casts (grade C).

The working group recommended that each team should choose an approach tailored to the family's social environment (availability of parents, proximity of a specialist team, care network, etc.) or adapt its own approach to this environment.

Irrespective of treatment modality, the need for surgery depends in part on the initial severity of the disorder (grade B), the expertise of the professionals treating the child, and the family's compliance with treatment (grade C). The Diméglio classification should be used to measure initial severity, progress over the first year and final outcome. Other outcome criteria may also be used particularly once the child has learnt to walk (agreement among professionals).

### **Vertical talus**

There are 2 different approaches for treating isolated vertical talus in children aged under 6 months:

- (i) functional treatment with a combination of mobilisation and removable braces
- (ii) treatment combining casting and mobilisation.

As the condition is rare, there are no studies comparing these two approaches. Surgery is common but not for infants under 6 months.

## **IV. CHOOSING REHABILITATION TECHNIQUES**

No longitudinal studies have compared the efficacy or iatrogenic risks of available rehabilitation techniques. The choice of technique depends on the diagnosis and severity of the disorder, preservation of normal joint structure, and the infant's psychomotor development.

### **IV.1. Passive manipulation**

In the case of passive joint limitation, passive manipulation should be used to stretch structures with poor extensibility and to reduce deformities. It should:

- be performed in traction on a relaxed child
- never oppose the child's spontaneous movement
- be painless
- be limited to the joints involved, avoiding any correction beyond normal range of movement, particularly in the adjacent joints.

For talipes equinovarus, mobilisations are performed in a specific order, irrespective of treatment approach:

- first, the calcaneopedal block is brought under the talus, using the lateral part of the talus for counter-support;
- then the equinus is gradually corrected.

### **IV.2. Active mobilisation**

In the event of a muscle deficiency, reflex automatic contraction can be obtained in deficient muscle groups by manual skin stimulation and by the use of balance reflexes and levels of motor development to implicate global motor patterns.

### **IV.3. Removable braces and plaster casts**

Removable braces are used as part of functional treatment or after serial casting. They maintain the correction achieved by casting or during mobilisation sessions. A brace should:

- be tailored to the individual
- not impinge on adjacent contralateral joints
- be completely painless
- have protective material placed on the skin before using adhesive tape. All allergenic products should be avoided.

There is no agreement among professionals on whether the brace should immobilise the knee.

For all braces and casts, professionals should ensure that the family is aware of:

- signs that the skin and blood vessels are not adversely affected;
- signs that the device is in the right position;
- what to do in the event of poor tolerance.



## **V. INFORMING AND INVOLVING PARENTS**

The working group recommended that:

- parents should be reassured about the functional prognosis for their child's foot as soon as the diagnosis is confirmed;
- the psychological impact of problems associated with long-term treatment on families should be kept in mind.

Irrespective of when the diagnosis is made, parents must be informed and reassured to ensure a relationship of trust, absence of feelings of guilt, and future cooperation. Information before the birth helps them welcome the child and arrange subsequent care. It is essential that parents should be involved in treatment by:

- attending follow-up or treatment appointments regularly;
- monitoring the child's tolerance of the brace or cast, and checking that it is properly positioned;
- possibly helping to apply braces and perform mobilisation (see conditions in Section V.2.).

### **V.1. Informing parents**

The working group recommended:

- that parents and all the professionals involved should be informed of the treatment chosen, its steps and how long it is likely to last. They may be able to meet other families with children with the same disorder;
- that, for the most severe disorders, the eventuality of sequelae, particularly morphological and functional, and of surgery be raised during the specialist orthopaedic consultation;
- that, for talipes equinovarus and vertical talus, the family should be told of the variety of treatment approaches available. The need for consistent continuous care should be stressed;
- that, for talipes equinovarus and vertical talus, application should be made for 100% reimbursement of costs by National Health Insurance from the time of the first specialist consultation.

### **V.2. Involving parents**

Families should only put on braces or carry out active or passive mobilisation if:

- they live far from professionals;
- they can learn the treatment procedure without affecting the parent-child relationship;
- they have been informed about the risk of inadequate correction to avoid any subsequent feelings of guilt.





## **VI. PROPOSALS FOR FUTURE ACTION**

The working group recommended that future cohorts should be monitored using the same clinical assessment criteria in order to be able to compare treatments in patient groups with a similar initial level of severity of deformity. The criteria are based on the Diméglio classification for talipes equinovarus and the Bleck classification for metatarsus adductus.

Prognostic factors for a favourable outcome (spontaneous or after treatment) are not well identified. The working group recommended that validation of clinical and functional classifications should continue, medical imaging methods (ultrasonography, MRI, radiology) should be developed and then validated to quantify the deformity after birth and identify potential prognostic factors.

Physiotherapy and orthopaedic treatment have not been compared. Mobilisation techniques have been well codified in the literature, while support braces vary widely. Comparing the various forms of support in terms of biomechanical relevance, safety, impact on quality of life of newborns and their families, and cost, would provide objective evidence-based criteria to assist in choosing between the different forms of support.

## ANNEX I. Bleck's classification of metatarsus adductus

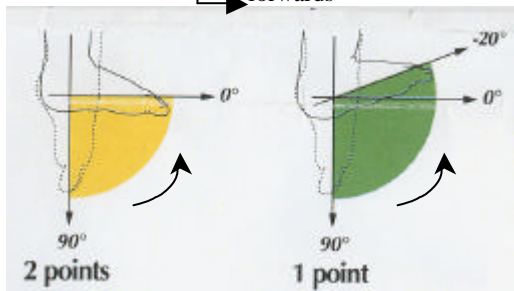
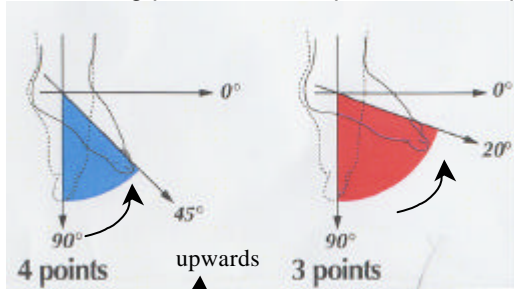
<b>SEVERITY OF DEFORMITY</b>	<b>Normal foot</b>	<b>Mild deformity</b>	<b>Moderate deformity</b>	<b>Severe deformity</b>
Observe in spontaneous position	Heel bisector passes between 2 <sup>nd</sup> and 3 <sup>rd</sup> toes = neutral position 	Heel bisector passes through 3 <sup>rd</sup> toe 	Heel bisector passes between 3 <sup>rd</sup> and 4 <sup>th</sup> toes 	Heel bisector falls beyond 4 <sup>th</sup> toe 
<b>STIFFNESS OF DEFORMITY</b>	<b>Normal mobility</b>	<b>Flexible</b>	<b>Partially reducible</b>	<b>Not reducible</b>
Observe reducibility of the deformity during passive manipulation of the forefoot	Full abduction of the tarso-metatarsal joint	The foot can be abducted passively beyond the neutral anatomical position	The foot can be corrected passively up to the neutral anatomical position	The lateral border of the foot remains convex during abduction. Neutral anatomical position cannot be attained

Bleck EE. Metatarsus adductus: classification and relationship to outcomes of treatment. *J Ped Orthop* 1983;3:2-9.

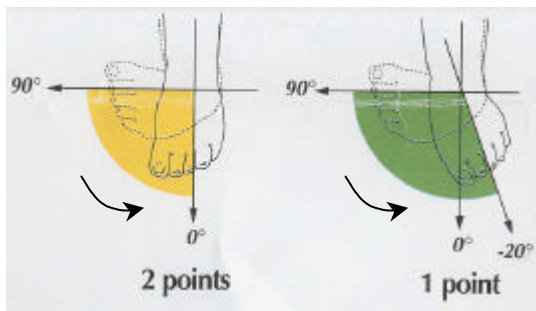
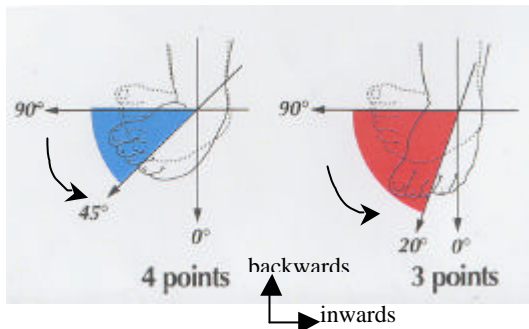
### Diméglio's classification of talipes equinovarus

Diagrams taken from: Diméglio A, Bonnet F. Rééducation du pied bot varus équin. Encyclopédie médico-chirurgicale (Elsevier SAS, Paris, all rights reserved): Kinésithérapie – Médecine Physique – Réadaptation, 1997;26-428-B-10:1-12 (by permission of Elsevier).

The scoring procedure is explained on the previous page.



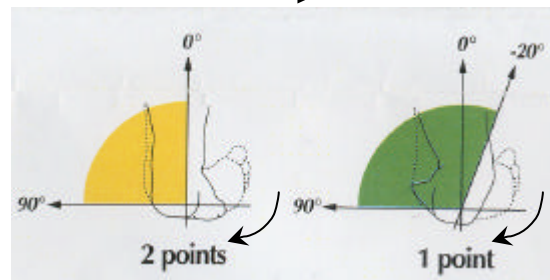
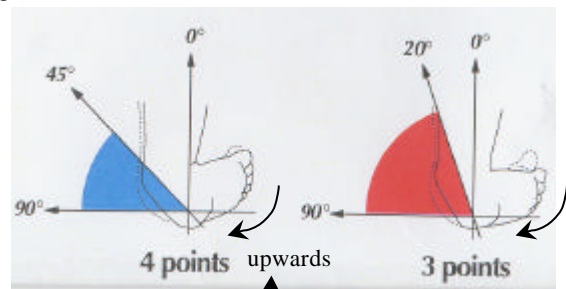
**4-point assessment of equinus**



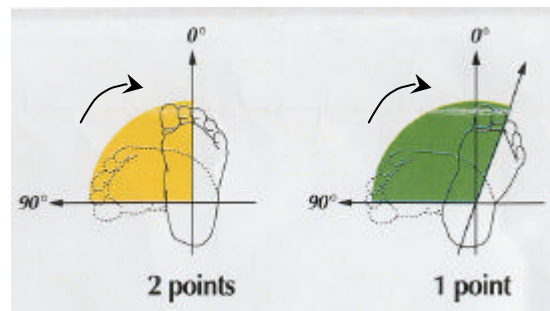
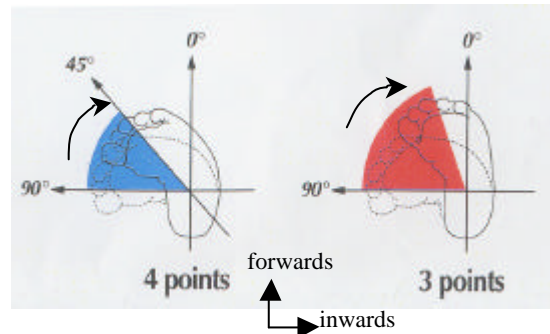
**4-point assessment of internal rotation (adduction) of the calcaneopedal block**

**Add 4 points for the following factors:**

- Posterior skin crease: 1 point
- Medial skin crease: 1 point
- Hollow plantar surface: 1 point
- Muscle deficiency (global hypertonia, severe amyotrophia, fibrous muscles): 1 point



**4-point assessment of hindfoot varus**



**4-point assessment of forefoot adduction**

**Classification :**

- Grade I: benign deformity, score < 5
- Grade II: moderate deformity, score = 5 to < 10
- Grade III: severe deformity, score = 10 to < 15
- Grade IV: very severe deformity, score = 15 to < 20

## ANNEX III. Foot deformity: decision criteria for defining treatment strategy by disorder

Disorder	Decision-making criteria to be investigated during specialist examination	Criteria suggesting child may be monitored by its own doctor	Family involvement	Criteria to decide whether child should see		Recommended treatment strategy
				physiotherapist and how soon	paediatric orthopaedic specialist	
(diagnosed by paediatrician or GP in maternity unit)	(by an orthopaedic surgeon, physio-therapist, specialist in physical and rehabilitation medicine or paediatrician)	(GP, paediatrician)				
<b>Talipes calcaneus or talipes calcaneo-valgus</b>	<ul style="list-style-type: none"> <li>• Degree of passive plantar flexion</li> <li>• Shape of the lateral border of the foot</li> </ul>	<ul style="list-style-type: none"> <li>• If plantar flexion &gt; 0°</li> <li>• If lateral border is straight</li> </ul>	<ul style="list-style-type: none"> <li>• No muscle stimulation (any stimulation reinforces global mobility in triple flexion) If plantar flexion &gt;0°</li> <li>• apply brace, if treated</li> </ul>	<ul style="list-style-type: none"> <li>• If plantar flexion &lt; 0° (passive manipulation cannot move the ankle into neutral position)</li> <li>• If lateral border of foot is concave</li> <li>• Start during first week of life</li> </ul>	<ul style="list-style-type: none"> <li>• At 2 mos if normal plantar flexion has not been achieved or if the lateral border of the foot is not straight</li> <li>• Aetiological workup for differential diagnosis with congenital vertical talus</li> </ul>	<p><i>Functional treatment</i></p> <ul style="list-style-type: none"> <li>• Passive mobilisation of the talocrural joint by a highly proximal grip</li> <li>• Passive stretching of anterior tibial and fibular muscles if there is valgus</li> <li>• Posterior brace if plantar flexion &lt; 0°</li> <li>• Anterior brace only when plantar flexion is &gt;0°</li> </ul> <p><i>Combined treatment if correction is insufficient after functional treatment</i></p>

Physiotherapy and orthopaedic treatment for isolated foot deformity during the first six months of life

Disorder	Decision-making criteria to be investigated during specialist examination	Criteria suggesting child may be monitored by its own doctor	Family involvement	Criteria to decide whether child should see		Recommended treatment strategy
				physiotherapist and how soon	paediatric orthopaedic specialist	
<b>Talipes varus</b>	<ul style="list-style-type: none"> <li>Degree of dorsiflexion at the ankle (by definition, this should be normal (&gt; 50°); otherwise see under "Talipes equinovarus")</li> </ul>	<ul style="list-style-type: none"> <li>For all cases of talipes varus</li> </ul>	<ul style="list-style-type: none"> <li>Stimulation of pronator muscles</li> </ul>	<ul style="list-style-type: none"> <li>Possibly to educate the family in stimulating the pronator muscles</li> <li>To be suggested in the maternity unit</li> </ul>	<ul style="list-style-type: none"> <li>At 2 months if there is supination or residual varus</li> <li>Aetiological workup for differential diagnosis with moderate talipes equinovarus</li> </ul>	<p><i>Functional treatment</i></p> <ul style="list-style-type: none"> <li>Reflex stimulation of pronator muscles</li> <li>No brace or cast</li> <li>No passive manipulation</li> </ul>
<b>Metatarsus adductus</b>	<p>According to Bleck's classification:</p> <ul style="list-style-type: none"> <li>spontaneous shape of lateral border of the foot</li> <li>reducibility of forefoot adduction during continuous passive motion</li> </ul>	<p>If metatarsus is mild and flexible:</p> <ul style="list-style-type: none"> <li>heel bisector passes through 3<sup>rd</sup> toe at rest</li> <li>adduction can be reduced by continuous passive motion up to neutral position</li> </ul>	<ul style="list-style-type: none"> <li>If metatarsus is mild and flexible: reflex stimulation of lateral muscles of the foot</li> <li>If metatarsus is rigid, moderate or severe: application of brace after learning how to do this; brace made by therapist</li> </ul>	<p>If metatarsus is rigid, moderate or severe:</p> <ul style="list-style-type: none"> <li>heel bisector passes between 3<sup>rd</sup> and 4<sup>th</sup> toes or more laterally</li> <li>passive reduction of forefoot adduction cannot reach neutral anatomical position</li> <li>to be started during 1<sup>st</sup> week of life</li> </ul>	<ul style="list-style-type: none"> <li>At 2 months if the lateral border of the foot has not become straight</li> <li>Aetiological workup for differential diagnosis with skewfoot</li> </ul>	<p><i>Functional treatment as 1<sup>st</sup> choice of treatment</i></p> <ul style="list-style-type: none"> <li>application of corrective brace, avoiding over-correction and hindfoot compensation</li> <li>realignment of the cuneometatarsal joint by passive manipulation</li> <li>passive stretching of medial foot muscles</li> </ul> <p><i>Treatment by casting or combination therapy if correction is insufficient after functional treatment</i></p>

Physiotherapy and orthopaedic treatment for isolated foot deformity  
during the first six months of life

Disorder	Decision-making criteria to be investigated during specialist examination	Criteria suggesting child may be monitored by its own doctor	Family involvement	Criteria to decide whether child should see		Recommended treatment strategy
				physiotherapist and how soon	paediatric orthopaedic specialist	
<b>Talipes equinovarus</b>	<ul style="list-style-type: none"> <li>• Score (Diméglio classification)</li> <li>• Newborn's social environment</li> <li>• Whether there is a specialist team nearby</li> </ul>	Needs routine monitoring by a specialist team who inform the child's doctor of the treatment strategy decided on and the criteria to be used for monitoring between specialist consultations	<ul style="list-style-type: none"> <li>• Regularity of consultations and rehabilitation sessions</li> <li>• Possible involvement in treatment, particularly if there is no network of specialist physiotherapists, under the following conditions: <ul style="list-style-type: none"> <li>- family willing to participate</li> <li>- they have been shown how to carry out the procedure and are competent</li> </ul> </li> </ul>	<ul style="list-style-type: none"> <li>• If functional treatment: daily session from 1<sup>st</sup> week</li> <li>• If treatment by casting: weekly assessment with application of new cast</li> </ul>	During the 1 <sup>st</sup> week, the newborn should be referred by the maternity unit for consultation with a paediatric orthopaedic specialist	<ul style="list-style-type: none"> <li>• Choice of treatment depends on the opinion of the paediatric orthopaedic specialist, based on the criteria given in column 1. Three possible treatment strategies: <ol style="list-style-type: none"> <li>(i) functional treatment - rehabilitation consists of passive mobilisation, active mobilisation and removable braces;</li> <li>(ii) serial casting (Ponseti's method);</li> <li>(iii) combination treatment – both rehabilitation and casting</li> </ol> </li> </ul>
<b>Vertical talus</b>	<ul style="list-style-type: none"> <li>• Score (Diméglio classification)</li> <li>• Newborn's social environment</li> <li>• Whether there is a specialist team nearby</li> </ul>	Needs routine monitoring by a specialist team who inform the child's own doctor of the treatment strategy decided on and the criteria to be used for monitoring between specialist consultations	Regularity of consultations and rehabilitation sessions Monitoring of braces	Routinely, from the 1 <sup>st</sup> week of life	During the 1 <sup>st</sup> week, the newborn should be referred by the maternity unit for consultation with a paediatric orthopaedic specialist	In the absence of clearly established clinical prognostic factors, treatment should be decided on a case by case basis